

CME

ACG Clinical Guideline: Diagnosis and Management of Gastrointestinal Subepithelial Lesions

Brian C. Jacobson, MD, MPH, FACG¹, Amit Bhatt, MD², Katarina B. Greer, MD, MS³, Linda S. Lee, MD⁴, Walter G. Park, MD, MS⁵, Bryan G. Sauer, MD, MSc, FACG⁶ and Vanessa M. Shami, MD, FACG⁶

Subepithelial lesions (SEL) of the GI tract represent a mix of benign and potentially malignant entities including tumors, cysts, or extraluminal structures causing extrinsic compression of the gastrointestinal wall. SEL can occur anywhere along the GI tract and are frequently incidental findings encountered during endoscopy or cross-sectional imaging. This clinical guideline of the American College of Gastroenterology was developed using the Grading of Recommendations Assessment, Development, and Evaluation process and is intended to suggest preferable approaches to a typical patient with a SEL based on the currently available published literature. Among the recommendations, we suggest endoscopic ultrasound (EUS) with tissue acquisition to improve diagnostic accuracy in the identification of solid nonlipomatous SEL and EUS fine-needle biopsy alone or EUS fine-needle aspiration with rapid on-site evaluation sampling of solid SEL. There is insufficient evidence to recommend surveillance vs resection of gastric gastrointestinal stromal tumors (GIST) <2 cm in size. Owing to their malignant potential, we suggest resection of gastric GIST >2 cm and all nongastric GIST. When exercising clinical judgment, particularly when statements are conditional suggestions and/or treatments pose significant risks, health-care providers should incorporate this guideline with patient-specific preferences, medical comorbidities, and overall health status to arrive at a patient-centered approach.

SUPPLEMENTARY MATERIAL accompanies this paper at <http://links.lww.com/AJG/C798>

Am J Gastroenterol 2023;118:46–58. <https://doi.org/10.14309/ajg.0000000000002100>; published online September 6, 2022

INTRODUCTION

The term subepithelial lesion (SEL) is used to describe a mass or mass-like structure that typically projects into the gastrointestinal (GI) lumen and arises from a nonmucosal layer within the GI tract wall. Structures adjacent to the GI tract can also cause extrinsic compression that mimic the appearance of SEL during endoscopy. Historically, SEL were termed “submucosal” because of their origin under the mucosa. With the introduction of endoscopic ultrasound (EUS), endoscopists gained the ability to distinguish distinct layers within the GI tract wall including the deep mucosa, submucosa, muscularis propria, and serosa or adventitia depending on the location. Because the submucosa is a specific layer, and not all SEL arise from the submucosal layer, the preferred term SEL came into broader use as the generic descriptor for intramural lesions. SEL are most often identified during endoscopy, although they may also be identified during cross-sectional imaging such as computed tomography (CT) and MRI.

SEL may be nonneoplastic, neoplastic but benign, neoplastic with malignant potential, or malignant (Table 1). When small, SEL rarely cause signs or symptoms and are typically incidental

findings. However, depending on their location and size, some may cause symptoms such as dysphagia, overt or occult gastrointestinal (GI) bleeding, and chronic anemia. Because the location of SEL typically precludes making a diagnosis through simple mucosal biopsies, they often present a diagnostic challenge. Nonetheless, through a combination of characteristic radiographic, endoscopic, and endosonographic appearances, coupled with judicious use of EUS-guided sampling, a definitive diagnosis can be made in most cases (Table 1). In some clinical situations (e.g., GI blood loss from the SEL), preresection diagnosis is not necessary because either endoscopic or surgical excision will be required regardless of etiology.

The purpose of this guideline is to aid clinicians with the decision-making process surrounding the diagnosis of SEL and to make management recommendations based on the latest available evidence. The diagnosis or management of SEL have been examined in previous guidelines and reviews (1,2). However, specific diagnostic and treatment recommendations have not been formally evaluated by the American College of Gastroenterology using the Grading of Recommendations, Assessment, Development, and Evaluation (GRADE) methodology (Table 2)

¹Division of Gastroenterology, Massachusetts General Hospital, Boston, Massachusetts, USA; ²Division of Gastroenterology, Cleveland Clinic, Cleveland, Ohio, USA; ³Department of Medicine, Section of Gastroenterology and Hepatology, Louis Stokes VA Medical Center, Cleveland, Ohio, USA; ⁴Division of Gastroenterology, Hepatology and Endoscopy, Brigham and Women’s Hospital, Boston, Massachusetts, USA; ⁵Division of Gastroenterology & Hepatology, Stanford University School of Medicine, Stanford, California, USA; ⁶University of Virginia, Charlottesville, VA, USA. **Correspondence:** Brian C. Jacobson, MD, MPH, FACG. E-mail: bcjacobson@mgh.harvard.edu.

Received April 4, 2022; accepted August 29, 2022

Table 1. Subepithelial lesions and causes of extrinsic compression

Subepithelial lesion or cause of extrinsic compression	Location in wall	Typical site(s) where found in GI tract ^a	Malignant potential	Tissue acquisition required for diagnosis
Spine	Extrinsic	Esophagus	No	No
Leiomyoma	MM, MP	Esophagus	No	Yes
Granular cell tumor	MM, SM	Esophagus	Yes (rare)	Yes
Duplication or bronchogenic cyst	Any including extrinsic	Esophagus/mediastinum	Yes (extremely rare)	No
Varices	SM	Esophagus	No	No
Xyphoid	Extrinsic	Fundus of stomach	No	No
Neuroendocrine tumor	SM, MP	Stomach, duodenum, rectum	Yes	Yes
GI stromal tumor	MM, MP	Stomach	Yes	Yes
Heterotopic pancreas	MM, SM, MP	Stomach (antrum)	Yes (extremely rare)	No
Schwannoma	SM, MP	Stomach	No	Yes
Gallbladder	Extrinsic	Antrum of stomach or Duodenal bulb	No	No
Lymphangioma	MP	Small intestine	No	Yes
Lipoma	SM	Colon	No	No
Metastasis	Any layer including extrinsic	Anywhere	Already malignant	Yes

GI, gastrointestinal; MM, muscularis mucosa; MP, muscularis propria; SM, submucosa.
^aWhile additional sites have been reported, this site(s) is the most common.

(3–5). This American College of Gastroenterology clinical guideline was developed to provide clinicians with the highest quality evidence available and to highlight gaps in our current understanding of the diagnosis and management of SEL.

SCOPE OF THE GUIDELINE AND METHODOLOGY

This guideline will address the major issues related to the diagnosis and management of SEL throughout the GI tract. Clinically relevant questions were developed by content experts whose clinical practice and research focus includes the care of patients with SEL. Along with research librarians, the panel formulated 15 questions deemed clinically important using the PICO format: P, population in question; I, intervention; C, comparator; and O, outcomes of interest (6,7). These questions were then investigated by performing a comprehensive literature search of EMBASE, PubMed, Cochrane Reviews, and the Cochrane Central Register of Controlled Clinical Trials from 2000 to December 31, 2020. A detailed explanation of our search strategy including citation yield is provided in the Supplementary Information (see Supplementary Information: Literature Search, <http://links.lww.com/AJG/C798>). We included only English-language articles that focused on human subjects. Preliminary results revealed large numbers of case reports/series, nonsystematic reviews, and unfortunately, few rigorous, evidence-based studies including randomized controlled trials, guidelines, and systematic reviews. By revising search strategies with additional clinical study type synonyms and phrases, the numbers of relevant study types increased somewhat, yielding 1,562 citations after deduplication. Application of inclusion/exclusion criteria based on study type ultimately provided 444 citations for review by the authors of this guideline. Our original 15 PICO questions evolved into a final

set of 11 recommendations based on duplicative topics and practical considerations (Table 3).

The GRADE process was used to assess the quality of evidence for each question by 2 formally trained GRADE methodologists (K.B.G. and B.G.S.) (3–5). The quality of evidence was graded as high when we were confident that the true effect lied close to that of the estimate of the effect, moderate when the true effect was likely to be close to the estimate of the effect, low when the true effect may be substantially different from the estimate of the effect, and very low when we had very little confidence in the effect estimate. Strong recommendations are offered when the desirable effects of the intervention clearly outweigh the undesirable effects, and conditional recommendations are offered when the trade-offs are less certain. Clinically, the strength of any specific recommendation was considered strong when consensus was that most patients should be managed according to the recommendation or conditional when some, but not all patients may derive benefit. In general, conditional recommendations require a thorough consideration of individual clinical situations. The strength of the recommendation derives from the quality of the evidence and an assessment of potential risks and benefits (3). Furthermore, a narrative evidence summary for each section provides important details for data supporting the statements.

The authors have also highlighted key concepts throughout the document that were not included in the GRADE assessment (Table 4). Key concepts are statements to which the GRADE process has not been applied and may include definitions and epidemiological statements rather than diagnostic or management recommendations.

An algorithm was developed to aid clinicians in the diagnosis and management of patients with SEL (Figure 1). Formal recommendations were incorporated into the algorithm where relevant.

Table 2. Grading of recommendations, assessment, development, and evaluation (GRADE) (80)

Strength of recommendation	Criteria
Factors influencing the strength of the recommendation include the quality of the evidence, clinical and patient-reported outcomes, and costs.	
Strong	Strong recommendations are offered when the desirable effects of an intervention clearly outweigh the undesirable effects.
Conditional	Conditional recommendations are offered when trade-offs are less certain—either because of low-quality evidence or because evidence suggests that desirable and undesirable effects are closely balanced.
Quality of evidence	Criteria
High	We are very confident that the true effect lies close to that of the estimate of the effect.
Moderate	We are moderately confident in the effect estimate: The true effect is likely to be close to the estimate of the effect, but there is a possibility that it is substantially different.
Low	Our confidence in the effect estimate is limited: The true effect may be substantially different from the estimate of the effect.
Very low	We have very little confidence in the effect estimate: The true effect is likely to be substantially different from the estimate of effect.

DIAGNOSIS OF SUBEPITHELIAL LESION

Recommendations

1. We suggest EUS be performed preferentially compared with endoscopy or contrast-enhanced cross-sectional imaging for the diagnosis of nonlipomatous SEL.
Conditional recommendation; very low quality of evidence
2. We do not recommend one type of echoendoscopy (forward viewing vs oblique viewing) when evaluating SEL.
Strong recommendation; low quality of evidence
3. We do not suggest bite-on-bite biopsies in the evaluation of SEL before EUS.
Conditional recommendation; very low quality of evidence
4. We suggest EUS with tissue acquisition to improve diagnostic accuracy in the identification of solid nonlipomatous SEL.
Conditional recommendation; very low quality of evidence
5. We suggest EUS fine-needle biopsy (FNB) alone or EUS fine-needle aspiration (FNA) with rapid on-site evaluation (ROSE) sampling of solid SEL compared with EUS-FNA without ROSE.
Conditional recommendation; low quality of evidence
6. We suggest using an unroofing technique when definitive diagnosis of a SEL is necessary and when EUS-FNA or FNB is nondiagnostic.
Conditional recommendation; low quality of evidence

SEL may be found incidentally or during an evaluation for signs and symptoms. Regardless of how a lesion is first identified, securing a diagnosis is typically necessary to determine appropriate management. In a minority of instances, the lesion will present with significant clinical symptoms or bleeding, justifying resection regardless of diagnosis (Figure 1). One exception to immediate resection for symptoms is in the setting of a very large GI stromal tumor (GIST), in which case a preresection definitive diagnosis may permit the use of neoadjuvant imatinib to reduce tumor size and aid in resection. In most cases, however, a diagnosis is sought to determine whether the appropriate management is simple clinical observation, active surveillance, or resection.

Key concept

1. If an SEL is causing symptoms or GI bleeding, then resection may be justified regardless of the size of the lesion and without a preresection diagnosis. The one exception is in the case of a large GIST, in which case tissue confirmation may be needed to permit the use of neoadjuvant imatinib to reduce tumor size.

Recommendation

1. We suggest EUS be performed preferentially compared with endoscopy or contrast-enhanced cross-sectional imaging for the diagnosis of nonlipomatous SEL (conditional recommendation; very low quality of evidence).

With the exception of lipomas, a definitive diagnosis based solely on an SEL's endoscopic and/or radiographic characteristics is not possible. Lipomas are the only solid lesions where such characteristics enable a definitive diagnosis. Lipomas can present anywhere within the GI tract, have a slightly yellow appearance on white light endoscopy, and demonstrate a "pillow sign" wherein the lipoma is easily deformed when pressed with a closed biopsy forceps akin to one's head indenting a pillow (8). In one small prospective study, endoscopy alone had a high specificity for the diagnosis of lipomas based on the presence or absence of a pillow sign (99%), although the sensitivity was low (40%) (9). While granular cell tumors and small neuroendocrine tumors may also exhibit a yellow appearance, they are typically firm and fail to demonstrate a pillow sign (10). On CT scan, a large lipoma will demonstrate Hounsfield units identical to fat. These findings may be sufficient to make a definitive diagnosis without the need for EUS or tissue sampling. Pancreatic rests, also known as ectopic pancreas, may also have a pathognomonic appearance when arising in the gastric antrum and exhibiting an umbilication. While their heterogenous, "pancreas-like" endosonographic appearance may be sufficient for diagnosis, FNA/FNB can often yield a definitive diagnosis. Their endoscopic appearance alone may not be reliable in distinguishing these SEL from other lesions such as GIST (11,12).

Previous studies have demonstrated that up to one-third of suspected SEL are extrinsic (13,14). Endoscopically, lesions extrinsic to the lumen often appear to move independently of the GI tract wall during patient respiration. For the determination of the location (specific intramural layer vs extrinsic to the GI lumen) of a suspected SEL, EUS is superior to endoscopy (9). In one international multicenter study, the sensitivity and specificity of

Table 3. Summary and strength of recommendations

Statement	GRADE quality of evidence	Strength of recommendation
Diagnosis		
1. We suggest EUS be performed preferentially compared with endoscopy or contrast-enhanced cross-sectional imaging for the diagnosis of nonlipomatous SEL.	Very low	Conditional
2. We do not recommend one type of echoendoscope (forward viewing vs oblique viewing) when evaluating SEL.	Low	Strong
3. We do not suggest bite-on-bite biopsies in the evaluation of SEL before EUS.	Very low	Conditional
4. We suggest EUS with tissue acquisition to improve diagnostic accuracy in the identification of solid nonlipomatous subepithelial lesions.	Very low	Conditional
5. We suggest EUS-FNB alone or EUS-FNA with ROSE sampling of solid subepithelial lesions compared with EUS-FNA without ROSE.	Low	Conditional
6. We suggest using an unroofing technique when definitive diagnosis of a subepithelial lesion is necessary and when EUS-FNA or FNB is nondiagnostic.	Low	Conditional
Therapy		
7. We suggest either submucosal tunneling endoscopic resection or surgical resection for the management of SEL originating from the muscularis propria layer of the esophagus and gastroesophageal junction when resection is necessary.	Very low	Conditional
8. There is insufficient evidence to recommend surveillance vs resection of GIST <2 cm in size. Owing to their malignant potential, we suggest the resection of gastric GIST >2 cm and all nongastric GIST.	Very low	Conditional
9. We suggest EMR or ESD for the resection of type 1 gNETs.	Very low	Conditional
10. We suggest ESD over EMR for the resection of low-grade, small type 3 gNETs without radiologic or EUS evidence of lymphadenopathy that do not undergo surgical resection.	Very low	Conditional

Table 3. (continued)

Statement	GRADE quality of evidence	Strength of recommendation
11. We do not suggest one type of endoscopic therapy (EMR vs ESD) for the resection of small (<1 cm), low-grade rectal neuroendocrine tumors.	Very low	Conditional
EMR, endoscopic mucosal resection; ESD, endoscopic submucosal dissection; EUS, endoscopic ultrasound; FNA, fine-needle aspiration; FNB, fine-needle biopsy; GIST, gastric gastrointestinal stromal tumors; gNET, gastric neuroendocrine tumor; GRADE, Grading of Recommendations Assessment, Development and Evaluation; ROSE, rapid on-site evaluation; SEL, subepithelial lesions.		

correctly differentiating an intramural from an extramural lesion with endoscopy alone was 87% and 29%, respectively. EUS improved the sensitivity and specificity to 92% and 100% (13).

Cross-sectional imaging alone has limited value in making a definitive diagnosis of SEL with the possible exception of lipomas and duplication cysts. In one case series that included 53 gastric SEL evaluated by both EUS and CT before laparoscopic wedge resection, the overall diagnostic accuracies of EUS imaging and CT were 64% and 51%, respectively ($P = 0.238$) with a median lesion size of 3 cm (15). In another series of 93 gastric SEL assessed by EUS, 55 also underwent preresection CT scanning. The sensitivity and specificity of contrast-enhanced CT for diagnosing neoplastic SEL was 80% and 81%, respectively (16). However, the mean size of neoplastic lesions detected and not detected by CT was 27 and 11 mm, respectively, indicating that CT alone performed quite poorly for the detection of small gastric SEL. Finally, in a study of 34 patients with gastric SEL who underwent both CT and EUS (EUS serving as the gold standard), CT had 85% sensitivity and 86% specificity simply for detecting the lesions (17). Taken together, the data suggest that while cross-sectional imaging may detect lesions identified incidentally during esophagogastroduodenoscopy (EGD), there is little diagnostic gain to pursuing such imaging over EUS.

Key concept

2. When seeking a diagnosis, contrast-enhanced imaging may add clinically useful information, but this should be reserved for situations when EUS is unavailable. In such instances, and depending on the differential diagnosis being considered, strong consideration should be given to referral to a center where EUS is available.

High-frequency ultrasound probes may be helpful in imaging small SEL whose size precludes tissue acquisition. The increased resolution but decreased depth of penetration afforded by these probes limits their use for imaging larger lesions. Other limitations include the inability to acquire tissue samples and lack of Doppler capabilities. One retrospective study suggested high diagnostic accuracy (92.6%) for high-frequency probes in diagnosing SEL (18). A more recent retrospective study of 20 MHz probes reported 80.1% diagnostic accuracy compared with pathology for upper GI SEL with the highest accuracy for lipomas

Table 4. Diagnosis and management of subepithelial lesions: key concepts

Key concept 1: If a SEL is causing symptoms or gastrointestinal bleeding, then resection may be justified regardless of the size of the lesion and without a preresection diagnosis. The one exception is in the case of a large GIST, in which case tissue confirmation may be needed to permit the use of neoadjuvant imatinib to reduce tumor size.

Key concept 2: When seeking a diagnosis, contrast-enhanced imaging may add clinically useful information, but this should be reserved for situations when EUS is unavailable. In such instances, and depending on the differential diagnosis being considered, strong consideration should be given to referral to a center where EUS is available.

Key concept 3: In the absence of a tissue diagnosis and/or resection of an SEL, the patient should be enrolled in some form of surveillance plan unless there is a high degree of confidence that the SEL has no malignant potential.

Key concept 4: There is no fixed cutoff in size below which FNA/FNB may not be attempted. Small SEL should be managed on a case-by-case basis depending on the location, ease of sampling, clinical history, perceived risks and benefits of a surveillance approach, and potential for primary endoscopic resection.

Key concept 5: For GIST <2 cm, if the clinical decision is to resect, endoscopic methods may be considered as acceptable alternative therapies compared with surgery. There is insufficient data to suggest any 1 endoscopic method as superior.

Key concept 6: Endoscopic resection of prominent type 2 gNET can be undertaken if the goal is debulking or management of ongoing blood loss. It is not clear whether ESD is superior to EMR in this setting, and choice of resection method may depend on local expertise.

EMR, endoscopic mucosal resection; ESD, endoscopic submucosal dissection; EUS, endoscopic ultrasound; FNA, fine-needle aspiration; FNB, fine-needle biopsy; GIST, gastric gastrointestinal stromal tumors; gNET, gastric neuroendocrine tumors; SEL, subepithelial lesions.

and pancreatic rests but only 63% accuracy for GIST (19). For colonic lesions, these probes may be helpful in the diagnosis of proximal colon SEL when forward-viewing echoendoscopes are unavailable (20).

Recommendation

2. We do not recommend one type of echoendoscope (forward viewing vs oblique viewing) when evaluating SEL (strong recommendation; low quality of evidence).

A forward-viewing echoendoscope may be helpful in negotiating postsurgical anatomy for upper GI SEL and evaluating proximal colonic SEL. Three randomized studies have compared forward-viewing echoendoscopes with standard oblique-viewing linear echoendoscopes with no significant differences in diagnostic yield for SEL (21–23). However, 1 crossover study of upper GI SEL reported the median procedure time was 6 minutes shorter when using a forward-viewing echoendoscope compared with that when using a standard linear echoendoscope (23). Another study confirmed shorter times to endosonographic visualization of upper GI SEL and subjectively superior image quality when using a forward-viewing instrument (22). While there may be certain situations that favor a forward-viewing echoendoscope, there is no clear superiority of one type over the other. Therefore, the choice of echoendoscope for any particular case should be left to the discretion of the operator.

Recommendation

3. We do not suggest bite-on-bite biopsies in the evaluation of SEL before EUS (conditional recommendation; very low quality of evidence).

Standard biopsy forceps typically fail to sample deeper than the mucosal layer of the GI tract, often yielding inadequate samples when trying to diagnose SEL. One potential technique to

overcome this entails removing the mucosa above the SEL with jumbo biopsy forceps and then performing repeat biopsies within the mucosal defect to attempt subepithelial sampling. This approach has been called the bite-on-bite technique and may provide better tissue quality sampling than EUS-FNA. To date, there has been only 1 prospective study evaluating the diagnostic utility of this technique (24). In this study, 93 subjects referred for EUS for an SEL were prospectively enrolled. Both EUS-FNA and biopsy sampling were performed after unroofing the mucosa with jumbo biopsy forceps. Among the 93 subjects, 72 underwent biopsies with a bite-on-bite technique, and diagnostic tissue was obtained for 66 (92%) without complications. By contrast, only 42 (58%) were technically amenable to EUS-FNA because of being either too small or too mobile. Of the 42, 34 (81%) underwent FNA that was deemed adequate by ROSE. Despite this, only 28 (67%) had sufficient material to render a diagnosis. While this study supports the possibility that bite-on-bite biopsies using jumbo forceps can yield diagnostic material, all bite-on-bite biopsies were performed after EUS that confirmed the lesion was not vascular or extrinsic to the GI tract. Hence, bite-on-bite biopsy with a jumbo forceps could be considered if EUS with FNB or FNA with ROSE is not feasible and if vascular lesions are excluded based on the clinical scenario and the endosonographic appearance.

Recommendation

4. We suggest EUS with tissue acquisition to improve diagnostic accuracy in the identification of solid nonlipomatous SEL (conditional recommendation; very low quality of evidence).

EUS imaging alone is inadequate to diagnose solid nonlipomatous SEL. Using pathological gold standards, EUS imaging without tissue acquisition has approximately 43%–50% diagnostic accuracy, 64%–80% sensitivity, and 77%–80% specificity for differentiating benign from malignant SEL (9,13,25–27). There are particular EUS findings associated with malignancy, especially in

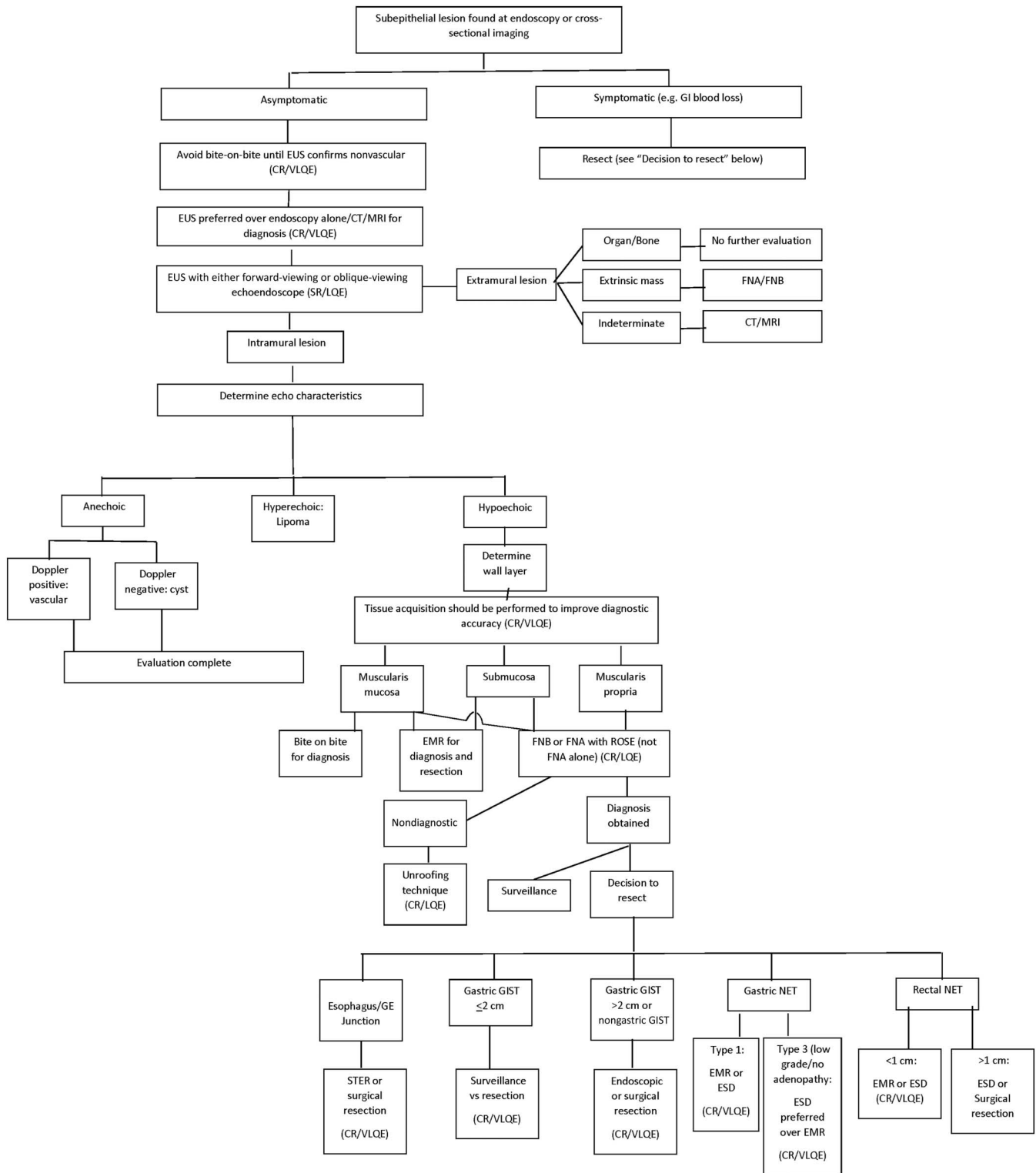


Figure 1. An evidence-based approach to the diagnosis and management of subepithelial lesions. CR, conditional recommendation; CT, computed tomography; EMR, endoscopic mucosal resection; ESD, endoscopic submucosal dissection; FNA, fine-needle aspiration; FNB, fine-needle biopsy; GE, gastroesophageal; GI, gastrointestinal; GIST, gastric gastrointestinal stromal tumors; LQE, low-quality evidence; ROSE, rapid on-site evaluation; SR, strong recommendation; STER, submucosal tunneling endoscopic resection; VLQE, very low-quality evidence; other abbreviations per text.

the setting of GIST, including a heterogeneous echotexture, large size (variably defined as >3 cm or >5 cm depending on the study), increasing size, and irregular margins (27,28). Additional EUS

findings specifically associated with malignant GIST include anechoic or cystic-appearing spaces, echogenic foci, irregular borders, and malignant-appearing lymph nodes. The presence of at least 2

of the findings such as irregular border, echogenic foci, and cystic spaces had sensitivity for malignancy in a GIST ranging from 80% to 100% (29). In the absence of all 3 EUS findings, malignancy was found only in 0%–11%. However, recent studies of 2–5 cm pathology-confirmed GIST failed to identify any EUS imaging findings that correlated with mitotic index (30,31). Tumor size is the only feature associated with higher mitotic index.

Interobserver variability further argues against EUS without tissue acquisition for the diagnosis of SEL. In one study, interobserver agreement was good to excellent for cysts and lipomas but only poor to fair for other SEL including leiomyomas and vascular lesions (32). The highest diagnostic sensitivity and specificity for EUS imaging is for lipomas (>90%) with lower sensitivity (76%) and specificity (85%) for GIST (33).

Although no randomized studies are available, the addition of tissue acquisition to EUS, whether by FNA or FNB, has been consistently shown to increase the diagnostic accuracy compared with EUS without tissue acquisition (25,26,34). The addition of tissue acquisition increases the diagnostic accuracy from a range of 30%–50% to a range of 73%–84% (34–37).

Tissue diagnosis is not always possible especially in smaller SEL. One retrospective study of 324 patients with upper GI SEL demonstrated the natural history of patients who underwent EUS imaging without tissue acquisition. Over a mean follow-up of 41 months, no patients developed malignancy (38). However, this study was limited by the fact that fewer than half of the patients were followed up long term. EUS imaging features relied upon by the endosonographer to decide whether tissue acquisition and/or resection of a lesion was required included size greater than 2 cm, hypoechogenicity, heterogeneity, and lobulation. Therefore, this study suggested small, homogenous-appearing SEL lacking worrisome features may be followed safely with a low risk for developing malignancy.

Key concept

3. In the absence of a tissue diagnosis and/or resection of an SEL, the patient should be enrolled in some form of surveillance plan unless there is a high degree of confidence that the SEL has no malignant potential.

Recommendation

5. We suggest EUS-FNB alone or EUS-FNA with ROSE sampling of solid nonlipomatous SEL compared with EUS-FNA without ROSE (conditional recommendation; low quality of evidence).

Core biopsy needles for EUS were introduced nearly 2 decades ago. Despite initial enthusiasm for them, technical issues with using the original 19-gauge Tru-cut needle (Cook Medical, Bloomington, IN) and lack of clear improved diagnostic yield led to further innovations with the development of newer core biopsy needles. The newer generation of core biopsy needles has uniquely designed cutting tips that improve tissue acquisition while being easier to deploy than earlier models (39).

A meta-analysis of 10 studies (including 6 randomized trials) with a total of 669 patients compared EUS-FNA with FNB of SEL (40). The authors demonstrated that FNB yields higher rates of adequate samples and histologic cores, yields greater diagnostic accuracy, and requires fewer numbers of needle passes. However,

when ROSE was available in these studies, no significant differences between FNA and FNB were noted in the abovementioned outcomes. It should be noted that another meta-analysis limited to upper GI SEL found no difference in diagnostic yield comparing FNA, Tru-cut core biopsies, and FNB regardless of needle size or use of ROSE (41).

Randomized studies have demonstrated higher diagnostic yield with FNB compared with FNA (42,43). One study randomized the first needle pass for tissue acquisition to FNA or reverse bevel FNB followed by alternating use of FNA or FNB and found FNB increased accuracy (90% vs 52%) and decreased the need for additional diagnostic procedures (14% vs 53%) and unnecessary surgical resections (6% vs 34%) (42). While ROSE was performed in only a minority of patients, FNA with ROSE had significantly lower sensitivity than FNB (66% compared with 93%). Another study focused on SEL >2 cm without ROSE and reported decreased numbers of passes with a higher diagnostic yield for FNB (43). An additional study randomized the first needle pass to FNA or reverse bevel FNB followed by use of the alternate needle, but with the uniform use of ROSE in all patients (44). In this study, FNB was associated with significantly fewer passes to achieve adequate tissue samples but no significant difference in diagnostic yield (82% for FNB vs 68% for FNA, $P = 0.49$). A retrospective study comparing a fork-tip biopsy needle to FNA reported a higher diagnostic yield for FNB compared with FNA (87% vs 53%, $P = 0.01$) (45).

Another consideration is the need for immunohistochemical or biomarker staining and quantification of mitotic figures, as might be required in the assessment of GIST. In general, material obtained by FNA can be spun in a centrifuge with the resulting pellet embedded in paraffin. Such material can then be assessed with typical histopathology techniques. This suggests both FNB and FNA remain options for the evaluation of GIST and other SEL even when staining and mitotic counts are required. One relatively small retrospective study found greater immunohistochemistry yield (89% vs 41%) of FNB over FNA when sampling GIST, but there was not a standardized technique to maximize FNA yield (46).

When FNA needles are used, the needle size itself may be an important consideration. One retrospective study compared 19- and 22-gauge FNA needles for gastric SEL in the fourth layer of the wall and demonstrated significantly higher diagnostic yield with the 19-gauge FNA needle (92% vs 71%) (47). Regarding FNB, there are insufficient data in the setting of SEL to know whether needle size correlates with diagnostic yield.

A consideration is whether a lesion is of sufficient size to enable EUS with FNA/FNB sampling. In general, the available literature has predominantly focused on lesions greater than 2 cm, although solid lesions smaller than 2 cm may be amenable to sampling depending on their location. Small lesions in the deep mucosa or submucosa may be resected by endoscopic methods to provide a definitive diagnosis (see further).

Key concept

4. There is no fixed cutoff in size below which FNA/FNB may not be attempted. Small SEL should be managed on a case-by-case basis depending on the location, ease of sampling, clinical history, perceived risks and benefits of a surveillance approach, and potential for primary endoscopic resection.

Recommendation

6. We suggest using an unroofing technique when a preresection definitive diagnosis of an SEL is necessary and when EUS-FNA or FNB is nondiagnostic (conditional recommendation; low quality of evidence).

The advent of endoscopic submucosal dissection (ESD) has engendered several novel methods for obtaining tissue from SEL when EUS-FNA or FNB fail to provide a diagnosis. Each of these involves some form of mucosal incision with exposure of the submucosa either for a direct biopsy of the SEL or to permit a tunneled approach to reach the SEL. Mucosal defects are typically closed postbiopsy, usually with hemoclips. While there has been a proliferation of various modifications to these techniques, each with a unique name, the basic principles remain.

A prospective cross-over study compared an ESD technique called submucosal tunnel biopsy with EUS with FNA among 43 subjects with gastric SEL (48). Patients with lipomas diagnosed by EUS or SEL >5 cm were excluded, and half of the subjects had a histologically proven GIST. The diagnostic yield of this technique, which allowed for cores of tissue obtained with a needle knife or biopsy forceps, was 100% compared with 35% with FNA ($P < 0.001$). The median procedure time was longer than FNA (37 vs 18 minutes, $P < 0.001$), and there were no differences in the rate of complications.

One nonrandomized prospective study compared submucosal tunnel biopsy with primary surgical resection among 68 patients with upper GI SEL (49). Submucosal tunnel biopsy was used in 40 patients achieving a diagnostic yield of 90% without complications. The results from submucosal tunnel biopsy altered the management of 14 patients (35%) with 13 patients avoiding surgery. Among the 28 patients who underwent primary surgical resection without a preoperative pathological diagnosis, 12 (43%) were confirmed to have benign lesions.

Mucosal incision–assisted biopsy (MIAB) is a technique where the mucosal layer is cut in a freehand fashion using a needle knife to expose the SEL for direct biopsy. A systematic review of MIAB that included 7 studies with a total of 159 patients reported a pooled diagnostic yield of 89% (95% confidence interval 83–94) (50). The studies included upper GI SEL in which GIST and leiomyomas represented the majority of lesions (39% and 25%, respectively). The mean tumor size was 2.1 cm, and 95% were located in the stomach. MIAB was associated with a 5% rate of GI bleeding.

A prospective, randomized, cross-over multicenter study compared MIAB with EUS-FNA for gastric SEL with a median tumor size of 2 cm (51). The investigators randomized 47 patients to either MIAB or EUS-FNA and observed a nonsignificant trend toward higher diagnostic yield with MIAB (91.3% vs 70.8%, $P = 0.07$). Complication rates were similar, but MIAB had a longer procedure time of 34 vs 26 minutes ($P = 0.001$). Another randomized study of 46 patients with upper GI SEL >2 cm also compared the MIAB technique (which they referred to as a “key-hole biopsy”) with EUS-FNA (52). Among the 20 patients with a surgical specimen as the gold standard, EUS-FNA had a 100% diagnostic accuracy compared with 91% for MIAB.

The current literature suggests that these unroofing techniques can provide a high diagnostic yield and are safe for those with specific training. Whether these techniques are superior to EUS-FNA or especially EUS-FNB remains unclear. One potential

limitation of any unroofing technique is that submucosal dissection results in local fibrosis, which may hamper future attempts at endoscopic resection, such as submucosal tunneling endoscopic resection (see further).

Note that these sampling techniques apply to situations when a preresection diagnosis is required. In some instances, particularly with small SEL confined to the deep mucosa or submucosa, primary endoscopic resection may be the preferred strategy for both diagnosis and treatment.

TREATMENT OF SUBEPITHELIAL LESIONS

Recommendations

7. We suggest either submucosal tunneling endoscopic resection (STER) or surgical resection for the management of SEL originating from the muscularis propria layer of the esophagus and gastroesophageal junction when resection is necessary. Conditional recommendation; very low quality of evidence
8. There is insufficient evidence to recommend surveillance vs resection of gastric GIST <2 cm in size. Owing to their malignant potential, we suggest resection of gastric GIST >2 cm and all nongastric GIST. Conditional recommendation; very low quality of evidence
9. We suggest endoscopic mucosal resection (EMR) or ESD for the resection of type 1 gastric neuroendocrine tumors (gNETs). Conditional recommendation; very low quality of evidence
10. We suggest ESD over EMR for the resection of low-grade, small type 3 gNETs without radiologic or EUS evidence of lymphadenopathy that do not undergo surgical resection. Conditional recommendation; very low quality of evidence
11. We do not suggest one type of endoscopic therapy (EMR vs ESD) for the resection of small (<1 cm), low-grade rectal neuroendocrine tumors (NETs). Conditional recommendation; very low quality of evidence

Asymptomatic benign SEL do not require resection. Other lesions with very low risk for malignant transformation can be managed on a case-by-case basis including consideration of the lesion’s size, resection risk, and the patient’s overall health. There is insufficient evidence to make definitive recommendations regarding surveillance intervals when resection is not undertaken. Some patients may prefer resection over lifelong surveillance, especially in the absence of long-term observational studies. Endoscopic resection has been performed successfully in the treatment of SEL. While initially developed to address mucosal-based lesions, advances in endoscopic techniques have allowed endoscopists to access and treat SEL from any wall layer of the GI tract. EMR involves elevating the lesion away from the muscularis propria before snare resection by injection of fluid into the submucosa, flooding the GI lumen with water, or the use of a banding device (53). Elevation of the lesion helps in tissue capture and is believed to limit thermal injury to deeper layers. ESD allows for precise control of both lateral and deep margin dissection with electrocautery knives, allowing removal of lesions *en bloc* with a significant likelihood of achieving negative margins (R0 resection) (54). STER adopts techniques from per oral endoscopic myotomy to form a submucosal tunnel allowing access to, and removal of, tumors arising from the muscularis propria layer, while keeping the integrity of the mucosa intact, avoiding a full thickness defect (55,56). This allows for safer endoscopic

resection of tumors from deeper layers of the GI lumen. Endoscopic full thickness resection (EFTR) technically allows for the resection of lesions from any wall layer of the GI lumen but requires sturdy closure to avoid perforation (57).

Recommendation

7. We suggest either STER or surgical resection for the management of SEL originating from the muscularis propria layer of the esophagus and gastroesophageal junction when resection is necessary (conditional recommendation; very low quality of evidence).

SEL arising from the muscularis propria of the esophagus or gastroesophageal junction are nearly always GIST or leiomyomas (Table 1). Endoscopic or surgical resection is required for symptomatic lesions and a subset of GIST (see further). Traditionally, thoracoscopic enucleation has been the standard treatment for SEL arising from these sites, although STER has now emerged as a therapeutic option. The potential advantages of STER over traditional ESD are the preservation of the integrity of the mucosal layer of the GI tract, thereby theoretically diminishing the chance of leaks and infectious complications. Studies directly comparing thoracoscopic enucleation with STER are limited and include 2 retrospective comparative studies (58,59) and 1 small prospective randomized trial (60).

One retrospective study compared the clinical outcomes of 166 patients who underwent STER ($n = 91$) or thoracoscopic enucleation (TE; $n = 75$) for large (>5 cm) symptomatic SEL in the esophagus and esophagogastric junction (59). While the tumor size in the STER group was slightly smaller than that in the TE group (median length and transverse diameters of 5.5 and 2 cm vs 6 and 3 cm, respectively), patient demographic data and other tumor characteristics were similar. The rate of successful *en bloc* resection was similar in both groups (STER = 84.6%, TE = 86.7%; $P = 0.71$), but the median time required for STER was significantly shorter than that for TE (78 vs 120 minutes; $P < 0.001$). In addition, the incidence of adverse events was similar between both groups (7.7% vs 5.3%; $P = 0.76$). The mean length of hospitalization was significantly shorter for those who underwent STER vs TE (4.6 vs 7.1 days, respectively; $P = 0.01$). The authors did note that tumors with a transverse diameter ≥ 3.5 cm and irregular shapes undergoing STER were more likely to result in technical difficulties, piecemeal resection, and adverse events.

In another retrospective study comparing STER with TE for esophageal SEL <40 mm in size, similar results were found (58). In this study, 74 subjects underwent STER while 52 underwent TE. Patient demographic data, tumor size, and *en bloc* resection rates (98.6% STER vs 100% TE; $P = 0.40$) were similar between both groups. Procedure duration and hospital length of stay were significantly shorter in the STER group (56 vs 123 minutes; $P < 0.001$ and 5 vs 10 days; $P = 0.009$). There were no significant differences in total costs or adverse events.

One study randomized patients with small (longest diameter ≥ 10 mm and transverse diameter ≤ 35 mm) esophageal SEL to STER ($n = 30$) or TE ($n = 28$) (60). The rate of successful *en bloc* resections was similar between both groups (83.3% STER vs 100% TE; $P = 0.14$). For lesions with transverse diameters ≥ 20.0 mm, STER only achieved a 71% *en bloc* resection rate. The median procedure duration and overall costs were less in the STER group compared with those in the TE group (45 vs 107 minutes; P

< 0.001 and \$4,499 vs \$6,137; $P < 0.001$). Because both STER and surgical resection are feasible techniques with comparable outcomes, the resection method may be driven by available local expertise.

Recommendation

8. There is insufficient evidence to recommend surveillance vs resection of gastric GIST < 2 cm in size. Owing to their malignant potential, we suggest resection of gastric GIST >2 cm and all nongastric GIST (conditional recommendation; very low quality of evidence).

Management of incidentally found GIST smaller than 2 cm remains controversial. The incidence of metastasis in lesions this size approaches 0% regardless of the mitotic rate (61). The National Comprehensive Cancer Network guidelines state that if there are no high-risk features by imaging such as irregular borders, cystic spaces, ulceration, echogenic foci, or heterogeneity (29), then endoscopic or radiographic surveillance is reasonable. However, in the presence of high-risk features, surgical resection is recommended (62).

Conversely, for GIST >2 cm, the rate of metastatic spread increases with the size of the lesion and may be as high as 86% for lesions greater than 10 cm with a high mitotic rate. For this reason, lesions >2 cm should be resected if the resection can be achieved with minimal morbidity. If not, neoadjuvant therapy may be indicated, underscoring the importance of a multidisciplinary approach to the management of GIST. One retrospective study compared the efficacy of ESD ($n = 75$) with laparoscopy ($n = 51$) in patients with small (≤ 2.1 cm) gastric GIST (63). Demographic data were similar between the 2 groups. The mean tumor size was similar (1.4 ± 0.7 cm in ESD group vs 1.5 ± 0.6 cm in the laparoscopy group; $P = 0.82$) as was follow-up time (3.3 and 3.4 years, respectively; $P = 0.19$). There was significantly decreased procedure time, blood loss, and hospital length of stay in the ESD group compared with that in the laparoscopy group (64 vs 79 minutes, $P = 0.04$; 8.5 vs 17.2 mL, $P = 0.01$; 6.6 vs 10.4 days, $P < 0.001$, respectively). Of importance, there was no significant difference in tumor recurrence rate over approximately 3 years.

Another retrospective study compared 3 resection approaches with gastric GIST <5 cm in size, assessing their safety, feasibility, and outcomes (64). Patients underwent ESD ($n = 46$), laparoscopic resection (LAP; $n = 30$), or a combined laparoscopic and endoscopic cooperative surgery ($n = 15$). Patients who underwent ESD had significantly smaller GIST compared with both the LAP and laparoscopic and endoscopic cooperative surgery groups. For example, the average GIST resected by ESD was 2.0 ± 0.8 cm compared with the average GIST resected by LAP, which was 3.7 ± 1.2 cm ($P < 0.001$). The operative time and intraoperative blood loss were significantly less in the ESD group, while the adverse event and tumor recurrence rates were similar among the 3 groups.

A 5-way retrospective comparison of techniques to resect GIST <5 cm included patients who underwent ESD ($n = 65$), endoscopic submucosal excavation (ESE; $n = 23$), EFTR ($n = 61$), LAP wedge resection ($n = 93$), and LAP subtotal gastrectomy ($n = 30$) (65). ESE is a modified ESD technique to expose the muscularis propria and then completely excavate the GIST along its lateral edges. Demographic data were similar among the

groups; however, the patients who underwent endoscopic resection (ESD, ESE, or EFTR) had smaller lesions (1.8 + 0.8 cm vs 3.4 + 1.2 cm), more intraluminal tumors (94% vs 62%), and fewer tumors that arose from the muscularis propria (55% vs 71%) than the patients who underwent surgical resection. The endoscopic resection group had a shorter hospital length of stay and diet recovery time, fewer blood transfusions, and lower hospitalization costs.

Finally, another retrospective study compared ESD (n = 68) with LAP (n = 47) in patients with gastric SEL originating from the muscularis propria (66). While demographic data were similar between the 2 treatment groups, tumor size was significantly larger in the LAP group than in the ESD group (37 vs 26 mm; $P = 0.04$). Patients who underwent ESD had decreased operative times, blood loss, hospital length of stay, and cost than those who underwent LAP regardless of lesion size (<2.0 cm or 2.0–5.0 cm). There were no significant differences in rates of *en bloc* resection, complete resection, or adverse events. Lack of long-term follow-up precludes assessment of recurrence rates.

Key concept

5. For GIST <2 cm, if the clinical decision is to resect, endoscopic methods may be considered as acceptable alternative therapies compared with surgery. There is insufficient data to suggest any 1 endoscopic method as superior.

Recommendation

9. We suggest EMR or ESD for the resection of type 1 gNETs (conditional recommendation; very low quality of evidence).

Initially termed GI carcinoid tumors by Oberndorfer in 1907 (67), these tumors show neuroendocrine differentiation and are now referred to as NETs. GI NET are generally indolent, but some can behave aggressively and metastasize. NET can occur anywhere along the GI tract, and their degree of aggressiveness, risk of lymph node metastasis, and management vary by their location of origin. In the stomach, NET are generally classified into 3 categories. Types 1 and 2 gNETs are associated with chronic hypergastrinemia. The elevated gastrin levels develop in response to atrophic gastritis in type 1 gNET (i.e. from antral G cells) and secondary to tumor-produced gastrin in type 2 gNET. Type 3 gNET are sporadic tumors that develop without hypergastrinemia and behave more aggressively than types 1 and 2 (68).

For type 1 gNET, the National Comprehensive Cancer Network recommends endoscopic resection of prominent tumors (69). Both EMR and ESD have been used for the treatment of type 1 gNET, and there have been several studies comparing these techniques. One retrospective study compared the clinical outcomes of 87 type 1 gNET ≤ 10 mm in size resected by EMR (n = 48) or ESD (n = 39) (70). The negative margin resection rate (R0 resection) was higher with ESD than with EMR, although this difference did not reach statistical significance (95% vs 83%, respectively, $P = 0.17$). Vertical margin involvement was statistically lower after ESD than after EMR (3% vs 17%, $P = 0.04$). A similar but smaller retrospective study compared EMR (n = 6) and ESD (n = 7) for type 1 gNET ≤ 10 mm also, finding a lower rate of vertical margin involvement after ESD compared with that after EMR (0% vs 67%, respectively) (71). While ESD may result in

higher R0 resection rates of type 1 gNET compared with EMR, the indolent nature of type 1 gNET makes it unclear whether this benefit results in a clinically meaningful difference.

Type 2 gNET are less common, accounting for approximately 5% of gNET and are often present in the setting of multiple endocrine neoplasia-1 syndrome. They have a low rate of metastasizing and are often multifocal, making endoscopic resection feasible but at times impractical.

Key concept

6. Endoscopic resection of prominent type 2 gNET can be undertaken if the goal is debulking or management of ongoing blood loss. It is not clear whether ESD is superior to EMR in this setting, and choice of resection method may depend on local expertise.

Recommendation

10. We suggest ESD over EMR for the resection of low-grade, small type 3 gNET without radiologic or EUS evidence of lymphadenopathy that do not undergo surgical resection (conditional recommendation; very low quality of evidence).

For type 3 gNET, endoscopic resection can be considered for superficial low-grade, small tumors (<1 cm) with no evidence of regional lymphadenopathy on EUS or other imaging. One retrospective study compared the clinical outcomes of 50 patients with type 3 gNET who underwent EMR (n = 41) or ESD (n = 9) (72). Positive histologic margins were seen in 7/41 (14.6%) in the EMR group and in 1/9 (11.1%) in the ESD group, although this difference did not reach statistical significance ($P = 0.249$). In combination with the studies of type 1 gNET, ESD may result in higher R0 resection rates than EMR. Given the more aggressive nature of type 3 gNET, a positive margin should lead to additional treatment with surgery. This would favor any endoscopic therapy with a higher rate of R0 resections. Therefore, when expertise is available, ESD should be considered for small, low-grade type 3 gNET.

Recommendation

11. We do not suggest one type of endoscopic therapy (EMR vs ESD) for the resection of small (<1 cm), low-grade rectal NET (conditional recommendation; very low quality of evidence).

Among all forms of NET, rectal NET are believed to have the best prognosis (73). The decision of how to resect rectal NET is largely based on the size of the lesion. A retrospective review of rectal NET found the risk of metastasis was 3% in tumors ≤ 10 mm, 66% in tumors 11–19 mm in size, and 73% in tumors ≥ 20 mm (74). Endoscopic resection of rectal NET is generally recommended when they are small (<1 cm). Some retrospective studies have found statistically higher R0 resection rates with ESD compared with those with EMR with submucosal injection and snare resection for small rectal NET (90%–97% vs 71%–77%, respectively), but longer procedure times for ESD vs EMR (11.4–20.44 vs 4.2–6.6 minutes, respectively) (75,76). However, 2 studies with a combined 159 patients compared band ligation EMR with ESD for the treatment of small rectal NET. Both

showed statistically significantly higher R0 resection rates with band ligation EMR compared with ESD (96%–100% R0 resection for EMR vs 54%–75% R0 resection for ESD) (77,78). The authors speculated that band EMR resection draws up more deep submucosal tissue for resection than can be achieved by ESD, but this remains speculative. More recently, a retrospective study compared underwater EMR with ESD for small rectal NET, finding both achieved an R0 resection in 86% of cases, but underwater EMR had significantly shorter procedure time than ESD (6 ± 3 vs 27 ± 13 minutes, $P < 0.001$) (79). Considering these studies, it would seem that both EMR and ESD resection can be considered for the treatment of small rectal NET, with band ligation or underwater EMR being the preferred forms if EMR is undertaken. Finally, while all rectal NET should be removed, EUS to assess for adenopathy may not be necessary in small (<1 cm), incidental rectal NET because primary excision is often performed during the initial colonoscopy when they are first encountered.

FUTURE DIRECTIONS

The quality of evidence from much of the SEL literature precluded us from making strong recommendations. This is not surprising when one considers the rarity of many forms of SEL, with low volume at most research facilities limiting the ability to conduct rigorous randomized controlled trials. The expanding ability to resect SEL through endoscopic methods such as ESD and use of full-thickness resection devices may diminish the need for accurate preresection diagnoses in some instances. Future studies should clarify the role of primary resection vs preresection diagnosis, whether there is a diagnostic role for artificial intelligence, and directly compare endoscopic resection methods. Identification of safe and efficient unroofing techniques may help expedite diagnoses and obviate the need for EUS in some cases. Head-to-head comparisons of endoscopic vs surgical resection techniques would better clarify their respective strengths and limitations and improve patient selection criteria. As new endoscopic tools and devices become available, a standardized lexicon of terminology should be developed, and attention should be paid to their potential application in the management of SEL.

ACKNOWLEDGEMENT

This guideline was produced in collaboration with the Practice Parameters Committee of the American College of Gastroenterology. The Committee gives special thanks to Preetika Sinh, MD, who served as the guideline monitor for this document.

CONFLICTS OF INTEREST

Guarantor of the article: Brian C. Jacobson, MD, MPH, FACP.

Specific author contributions: All authors contributed to literature review, rating evidence, drafting the manuscript, and approving final version. B.G.S. and K.B.G. also provided specific expertise in the GRADE process and performed the literature searches.

Financial support: None to report.

Potential competing interests: None to report.

REFERENCES

- Chandrasekhara V, Faulx AL, Kothari S, et al. The role of endoscopy in subepithelial lesions of the GI tract. *Gastrointest Endosc* 2017;85(6):1117–32.
- Kim SY, Kim KO. Management of gastric subepithelial tumors: The role of endoscopy. *World J Gastrointest Endosc* 2016;8(11):418–24.
- Guyatt GH, Oxman AD, Kunz R, et al. Going from evidence to recommendations. *BMJ* 2008;336(7652):1049–51.
- Guyatt GH, Oxman AD, Kunz R, et al. What is “quality of evidence” and why is it important to clinicians? *BMJ* 2008;336(7651):995–8.
- Guyatt GH, Oxman AD, Vist GE, et al. Grade: An emerging consensus on rating quality of evidence and strength of recommendations. *BMJ* 2008;336(7650):924–6.
- Richardson WS, Wilson MC, Nishikawa J, et al. The well-built clinical question: A key to evidence-based decisions. *ACP J Club* 1995;123(3):A12–3.
- Higgins JPTJ, Chandler J, Cumpston M, et al. *Cochrane Handbook for Systematic Reviews of Interventions Version 6.2*. Updated February 2021. Cochrane 2021.
- Alkhatib AA, Faigel DO. Endoscopic ultrasonography-guided diagnosis of subepithelial tumors. *Gastrointest Endosc Clin N Am* 2012;22(2):187–205.
- Hwang JH, Saunders MD, Rulyak SJ, et al. A prospective study comparing endoscopy and EUS in the evaluation of GI subepithelial masses. *Gastrointest Endosc* 2005;62(2):202–8.
- Kim DU, Kim GH, Ryu DY, et al. Endosonographic features of esophageal granular cell tumors using a high-frequency catheter probe. *Scand J Gastroenterol* 2011;46(2):142–7.
- Attwell A, Sams S, Fukami N. Diagnosis of ectopic pancreas by endoscopic ultrasound with fine-needle aspiration. *World J Gastroenterol* 2015;21(8):2367–73.
- Chou JW, Cheng KS, Ting CF, et al. Endosonographic features of histologically proven gastric ectopic pancreas. *Gastroenterol Res Pract* 2014;2014:160601–7.
- Rosch T, Kapfer B, Will U, et al. New techniques accuracy of endoscopic ultrasonography in upper gastrointestinal submucosal lesions: A prospective multicenter study. *Scand J Gastroenterol* 2002;37(7):856–62.
- Motoo Y, Okai T, Ohta H, et al. Endoscopic ultrasonography in the diagnosis of extraluminal compressions mimicking gastric submucosal tumors. *Endoscopy* 1994;26(02):239–42.
- Kim SY, Shim KN, Lee JH, et al. Comparison of the diagnostic ability of endoscopic ultrasonography and abdominopelvic computed tomography in the diagnosis of gastric subepithelial tumors. *Clin Endosc* 2019;52(6):565–73.
- Goto O, Kambe H, Niimi K, et al. Discrepancy in diagnosis of gastric submucosal tumor among esophagogastroduodenoscopy, CT, and endoscopic ultrasonography: A retrospective analysis of 93 consecutive cases. *Abdom Imaging* 2012;37(6):1074–8.
- Okten RS, Kacar S, Kucukay F, et al. Gastric subepithelial masses: Evaluation of multidetector CT (multiplanar reconstruction and virtual gastroscopy) versus endoscopic ultrasonography. *Abdom Imaging* 2012;37(4):519–30.
- Xu GQ, Li YW, Han YM, et al. Miniature ultrasonic probes for diagnosis and treatment of digestive tract diseases. *World J Gastroenterol* 2004;10(13):1948–53.
- Khan S, Zhang R, Fang W, et al. Reliability of endoscopic ultrasound using miniprobe and grayscale histogram analysis in diagnosing upper gastrointestinal subepithelial lesions. *Gastroenterol Res Pract* 2020;2020:6591341–9.
- Chen TH, Lin CJ, Wu RC, et al. The application of miniprobe ultrasonography in the diagnosis of colorectal subepithelial lesions. *Chang Gung Med J* 2010;33(4):380–8.
- Larghi A, Ibrahim M, Fuccio L, et al. Forward-viewing echoendoscope versus standard echoendoscope for endoscopic ultrasound-guided tissue acquisition of solid lesions: A randomized, multicenter study. *Endoscopy* 2019;51(5):444–51.
- Lee SK, Seo DW, Choi J-H, et al. Evaluation of the feasibility and efficacy of forward-viewing endoscopic ultrasound. *Gut Liver* 2015;9(5):679–84.
- Matsuzaki I, Miyahara R, Hirooka Y, et al. Forward-viewing versus oblique-viewing echoendoscopes in the diagnosis of upper GI subepithelial lesions with EUS-guided FNA: A prospective, randomized, crossover study. *Gastrointest Endosc* 2015;82(2):287–95.
- Komanduri S, Keefer L, Jakate S. Diagnostic yield of a novel jumbo biopsy “unroofing” technique for tissue acquisition of gastric submucosal masses. *Endoscopy* 2011;43(10):849–55.
- Karaca C, Turner BG, Cizginer S, et al. Accuracy of EUS in the evaluation of small gastric subepithelial lesions. *Gastrointest Endosc* 2010;71(4):722–7.
- Reddydasu SC, Oropeza-Vail M, Paksresht K, et al. Are endoscopic ultrasonography imaging characteristics reliable for the diagnosis of small upper gastrointestinal subepithelial lesions? *J Clin Gastroenterol* 2012;46(1):42–5.

27. Brand B, Oesterhelweg L, Binmoeller KF, et al. Impact of endoscopic ultrasound for evaluation of submucosal lesions in gastrointestinal tract. *Dig Liver Dis* 2002;34(4):290–7.
28. Faigel DO, Abulhawa S. Gastrointestinal stromal tumors: The role of the gastroenterologist in diagnosis and risk stratification. *J Clin Gastroenterol* 2012;46(8):629–36.
29. Chak A, Canto MI, Rosch T, et al. Endosonographic differentiation of benign and malignant stromal cell tumors. *Gastrointest Endosc* 1997; 45(6):468–73.
30. Seven G, Arici DS, Senturk H. Correlation of endoscopic ultrasonography features with the mitotic index in 2- to 5-cm gastric gastrointestinal stromal tumors. *Dig Dis* 2022;40(1):14–22.
31. Kim MN, Kang SJ, Kim SG, et al. Prediction of risk of malignancy of gastrointestinal stromal tumors by endoscopic ultrasonography. *Gut Liver* 2013;7(6):642–7.
32. Gress F, Schmitt C, Savides T, et al. Interobserver agreement for EUS in the evaluation and diagnosis of submucosal masses. *Gastrointest Endosc* 2001;53(1):71–6.
33. Seo SW, Hong SJ, Han JP, et al. Accuracy of a scoring system for the differential diagnosis of common gastric subepithelial tumors based on endoscopic ultrasonography. *J Dig Dis* 2013;14(12):647–53.
34. Attila T, Aydin O. Lesion size determines diagnostic yield of EUS-FNA with onsite cytopathologic evaluation for upper gastrointestinal subepithelial lesions. *Turk J Gastroenterol* 2018;29(4):436–41.
35. Larghi A, Verna EC, Ricci R, et al. EUS-guided fine-needle tissue acquisition by using a 19-gauge needle in a selected patient population: A prospective study. *Gastrointest Endosc* 2011;74(3):504–10.
36. Lim TW, Choi CW, Kang DH, et al. Endoscopic ultrasound without tissue acquisition has poor accuracy for diagnosing gastric subepithelial tumors. *Medicine (Baltimore)* 2016;95(44):e5246.
37. Hoda KM, Rodriguez SA, Faigel DO. EUS-guided sampling of suspected GI stromal tumors. *Gastrointest Endosc* 2009;69(7):1218–23.
38. Dias de Castro F, Magalhaes J, Monteiro S, et al. The role of endoscopic ultrasound in the diagnostic assessment of subepithelial lesions of the upper gastrointestinal tract. *GE Port J Gastroenterol* 2016;23(6):287–92.
39. Navaneethan U, Hwang JH, Aslanian HR, et al. Devices for use with EUS. *VideoGIE* 2017;2(3):35–45.
40. Facciorusso A, Sunny SP, Del Prete V, et al. Comparison between fine-needle biopsy and fine-needle aspiration for EUS-guided sampling of subepithelial lesions: A meta-analysis. *Gastrointest Endosc* 2020;91(1): 14–22 e2.
41. Zhang XC, Li QL, Yu YF, et al. Diagnostic efficacy of endoscopic ultrasound-guided needle sampling for upper gastrointestinal subepithelial lesions: A meta-analysis. *Surg Endosc* 2016;30(6):2431–41.
42. Hedenstrom P, Marschall HU, Nilsson B, et al. High clinical impact and diagnostic accuracy of EUS-guided biopsy sampling of subepithelial lesions: A prospective, comparative study. *Surg Endosc* 2018;32(3): 1304–13.
43. Kim GH, Cho YK, Kim EY, et al. Comparison of 22-gauge aspiration needle with 22-gauge biopsy needle in endoscopic ultrasonography-guided subepithelial tumor sampling. *Scand J Gastroenterol* 2014;49(3): 347–54.
44. Han JP, Lee TH, Hong SJ, et al. EUS-guided FNA and FNB after on-site cytological evaluation in gastric subepithelial tumors. *J Dig Dis* 2016; 17(9):582–7.
45. El Chafic AH, Loren D, Siddiqui A, et al. Comparison of FNA and fine-needle biopsy for EUS-guided sampling of suspected GI stromal tumors. *Gastrointest Endosc* 2017;86(3):510–5.
46. Trindade AJ, Benias PC, Alshelleh M, et al. Fine-needle biopsy is superior to fine-needle aspiration of suspected gastrointestinal stromal tumors: A large multicenter study. *Endosc Int Open* 2019;07(07):E931–36.
47. Lopes CV, Hartmann AA, Artifon ELdA. Eus-fna with 19 or 22 gauges needles for gastric subepithelial lesions of the muscle layer. *Arq Bras Cir Dig* 2018;31(1):e1350.
48. Kobara H, Mori H, Nishimoto N, et al. Comparison of submucosal tunneling biopsy versus EUS-guided FNA for gastric subepithelial lesions: A prospective study with crossover design. *Endosc Int Open* 2017;05(08): E695–E705.
49. Tae HJ, Lee HL, Lee KN, et al. Deep biopsy via endoscopic submucosal dissection in upper gastrointestinal subepithelial tumors: A prospective study. *Endoscopy* 2014;46(10):845–50.
50. Dhaliwal A, Kolli S, Dhindsa BS, et al. Clinical efficacy and safety of mucosal incision-assisted biopsy for the diagnosis of upper gastrointestinal subepithelial tumors: A systematic review and meta-analysis. *Ann Gastroenterol* 2020;33(2):155–61.
51. Osoegawa T, Minoda Y, Ihara E, et al. Mucosal incision-assisted biopsy versus endoscopic ultrasound-guided fine-needle aspiration with a rapid on-site evaluation for gastric subepithelial lesions: A randomized cross-over study. *Dig Endosc* 2019;31(4):413–21.
52. Zoundjiekpon V, Falt P, Fojtik P, et al. Endosonography-Guided Fine-Needle Aspiration versus “Key-Hole Biopsy” in the diagnostics of upper gastrointestinal subepithelial tumors. A prospective randomized interventional study. *Biomed Pap Med Fac Univ Palacky Olomouc Czech Repub* 2020;164(1):63–70.
53. Fujii-Lau LL, Hwang JH, Konda V, et al. Endoscopic mucosal resection. *Gastrointest Endosc* 2015;82(2):215–26.
54. Bhatt A, Abe S, Kumaravel A, et al. Indications and techniques for endoscopic submucosal dissection. *Am J Gastroenterol* 2015;110(6): 784–91.
55. Xu MD, Cai MY, Zhou PH, et al. Submucosal tunneling endoscopic resection: A new technique for treating upper GI submucosal tumors originating from the muscularis propria layer (with videos). *Gastrointest Endosc* 2012;75(1):195–9.
56. Inoue H, Ikeda H, Hosoya T, et al. Submucosal endoscopic tumor resection for subepithelial tumors in the esophagus and cardia. *Endoscopy* 2012;44(03):225–30.
57. Schmidt A, Bauerfeind P, Gubler C, et al. Endoscopic full-thickness resection in the colorectum with a novel over-the-scope device: First experience. *Endoscopy* 2015;47(08):719–25.
58. Li QY, Meng Y, Xu YY, et al. Comparison of endoscopic submucosal tunneling dissection and thoracoscopic enucleation for the treatment of esophageal submucosal tumors. *Gastrointest Endosc* 2017;86(3): 485–91.
59. Chen T, Lin ZW, Zhang YQ, et al. Submucosal tunneling endoscopic resection vs thoracoscopic enucleation for large submucosal tumors in the esophagus and the esophagogastric junction. *J Am Coll Surg* 2017;225(6): 806–16.
60. Chai N, Du C, Gao Y, et al. Comparison between submucosal tunneling endoscopic resection and video-assisted thoracoscopic enucleation for esophageal submucosal tumors originating from the muscularis propria layer: A randomized controlled trial. *Surg Endosc* 2018;32(7):3364–72.
61. Miettinen M, Lasota J. Gastrointestinal stromal tumors: Pathology and prognosis at different sites. *Semin Diagn Pathol* 2006;23(2):70–83.
62. NCCN (https://www.nccn.org/login?ReturnURL=https://www.nccn.org/professionals/physician_gls/pdf/gist.pdf). Accessed March 3, 2022.
63. Meng Y, Li W, Han L, et al. Long-term outcomes of endoscopic submucosal dissection versus laparoscopic resection for gastric stromal tumors less than 2 cm. *J Gastroenterol Hepatol* 2017;32(10):1693–7.
64. Yin X, Yin Y, Chen H, et al. Comparison analysis of three different types of minimally invasive procedures for gastrointestinal stromal tumors ≤ 5 cm. *J Laparoendosc Adv Surg Tech A* 2018;28(1):58–64.
65. Bian C, Zhang H, Huang X, et al. Comparison between laparoscopic and endoscopic resections for gastric submucosal tumors. *Saudi J Gastroenterol* 2019;25(4):245–50.
66. Meng FS, Zhang ZH, Hong YY, et al. Comparison of endoscopic submucosal dissection and surgery for the treatment of gastric submucosal tumors originating from the muscularis propria layer: A single-center study (with video). *Surg Endosc* 2016;30(11):5099–107.
67. Oberndorfer S. Karzinoide tumoren des dunndarms. *Frankf Z Pathol* 1907:426–32.
68. Rindi G, Luinetti O, Cornaggia M, et al. Three subtypes of gastric argyrophilic carcinoid and the gastric neuroendocrine carcinoma: A clinicopathologic study. *Gastroenterology* 1993;104(4):994–1006.
69. Shah MH, Goldner WS, Halfdanarson TR, et al. NCCN guidelines insights: Neuroendocrine and adrenal tumors, version 2.2018. *J Natl Compr Canc Netw* 2018;16(6):693–702.
70. Kim HH, Kim GH, Kim JH, et al. The efficacy of endoscopic submucosal dissection of type I gastric carcinoid tumors compared with conventional endoscopic mucosal resection. *Gastroenterol Res Pract* 2014;2014:1–7.
71. Sato Y, Takeuchi M, Hashimoto S, et al. Usefulness of endoscopic submucosal dissection for type I gastric carcinoid tumors compared with endoscopic mucosal resection. *Hepatogastroenterology* 2013;60(126): 1524–9.
72. Kwon MJ, Kang HS, Soh JS, et al. Lymphovascular invasion in more than one-quarter of small rectal neuroendocrine tumors. *World J Gastroenterol* 2016;22(42):9400–10.

73. Man D, Wu J, Shen Z, et al. Prognosis of patients with neuroendocrine tumor: A SEER database analysis. *Cancer Manag Res* 2018;10:5629–38.
74. Gleeson FC, Levy MJ, Dozois EJ, et al. Endoscopically identified well-differentiated rectal carcinoid tumors: Impact of tumor size on the natural history and outcomes. *Gastrointest Endosc* 2014;80(1):144–51.
75. Zhang J, Liu M, Li H, et al. Comparison of endoscopic therapies for rectal carcinoid tumors: Endoscopic mucosal resection with circumferential incision versus endoscopic submucosal dissection. *Clin Res Hepatol Gastroenterol* 2018;42(1):24–30.
76. Park HW, Byeon JS, Park YS, et al. Endoscopic submucosal dissection for treatment of rectal carcinoid tumors. *Gastrointest Endosc* 2010;72(1):143–9.
77. Bang BW, Park JS, Kim HK, et al. Endoscopic resection for small rectal neuroendocrine tumors: Comparison of endoscopic submucosal resection with band ligation and endoscopic submucosal dissection. *Gastroenterol Res Pract* 2016;2016:1–6.
78. Lim HK, Lee SJ, Baek DH, et al. Resectability of rectal neuroendocrine tumors using endoscopic mucosal resection with a ligation band device and endoscopic submucosal dissection. *Gastroenterol Res Pract* 2019; 2019:1–10.
79. Park SS, Han KS, Kim B, et al. Comparison of underwater endoscopic mucosal resection and endoscopic submucosal dissection of rectal neuroendocrine tumors (with videos). *Gastrointest Endosc* 2020;91(5): 1164–71.e2.
80. Balshem H, Helfand M, Schunemann HJ, et al. GRADE guidelines: 3. Rating the quality of evidence. *J Clin Epidemiol* 2011; 64(4):401–6.